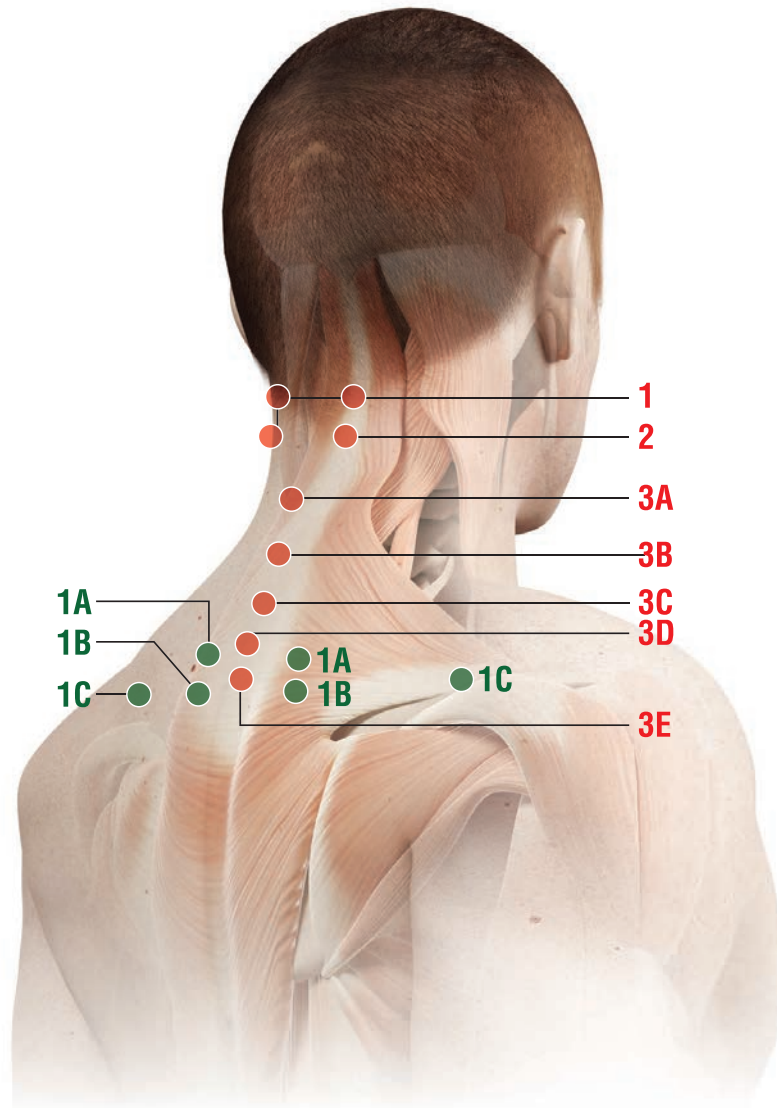




THERAPEUTIC ATLAS

CERVICAL REGION




MD-NECK



Remarks:

Subcutaneous (**s.c.**) and intradermal injections: use a 12-16mm, 25-28G needle.

Intramuscular (**i.m.**) injections: use a 40mm, 21G needle

- When making subcutaneous injections, insert the needle at approximately a 45° degree angle ();
- When making intradermal injections, insert the needle at approximately a 30° degree angle ();
- When making intramuscular injections, insert the needle at approximately a 90° degree angle ().

● SECONDARY POINTS

1

Anatomical landmarks:

- A) 3-4 cm lateral to the space between the spinous processes of C6 and C7 (bilateral)
- B) 3-4 cm lateral to the space between the spinous processes of C7 and T1 (bilateral)
- C) midway along the line joining the spinous process of C7 and the acromion.

MDs:

MD-Muscle

MD-Muscle + MD-Neural if neck pain radiates to the trapezius muscle unilaterally or bilaterally

How to inject: i.d. at a depth of 5-6 mm.

● MAIN POINTS

1

Anatomical landmark:

Below the external occipital protuberance, in the muscle insertion, just below the transverse process of the atlas.

How to inject: s.c.

2

Anatomical landmarks:

3-4 cm lateral to the space between the spinous processes of C2 and C3.

How to inject: s.c.

3

Anatomical landmarks:

- From the top:

- A) below the spinous process of C2
- B) below the spinous process of C4
- C) below the spinous process of C5
- D) below the spinous process of C6
- E) below the spinous process of C7.

How to inject: i.d.

CERVICAL REGION – MD-NECK

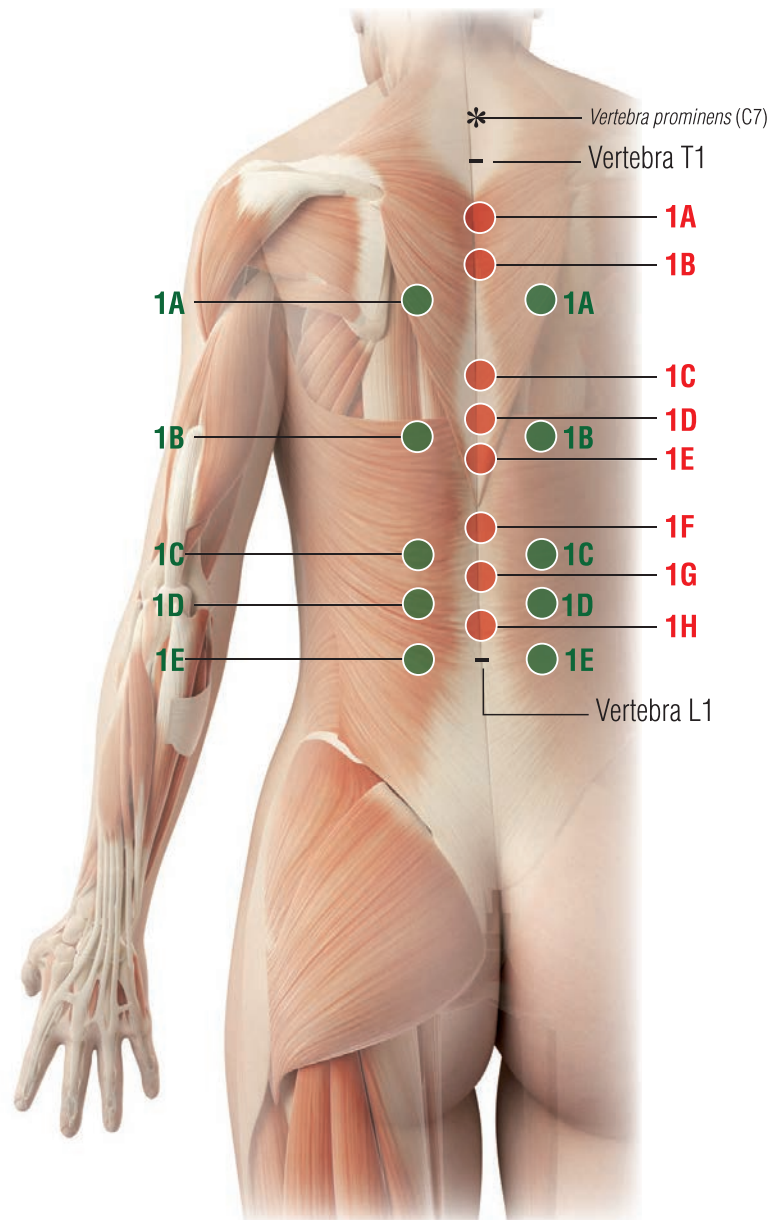
POSSIBLE COMBINATIONS WITH OTHER GUNA COLLAGEN MDs

- Injection in the **main points**

- Neck pain due to cartilage degenerative cervical spine disorders (cervical osteoarthritis):
MD-Neck + MD-Poly
- Neck pain due to cervical muscular trigger points:
MD-Neck + MD-Muscle
- Stiff neck syndrome:
MD-Neck + MD-Muscle + MD-Neural
- Neck pain due to muscle tension:
MD-Neck + MD-Neural + MD-Muscle
- Whiplash:
MD-Neck + MD-Neural + MD-Muscle
- Postural neck ache:
MD-Neck + MD-Neural + MD-Muscle + MD-Tissue
- Mechanical imbalance (facet joint syndrome):
MD-Neck + MD-Neural
- Cervical spinal ligament syndrome:
MD-Neck + MD-Neural + MD-Matrix
- Cervical spinal nerve root pain:
MD-Neck + MD-Neural.

THORACIC REGION

MD-THORACIC



Remarks:

1. For the numbering of the spinous processes of the vertebrae indicated in Main Points and Secondary Points, you can start from the vertebra prominens*: spinous process of C7; in full anterior cervical flexion this is the main and most prominent landmark. It's the most important landmark of the whole spine.
2. Subcutaneous (**s.c.**) and intradermal (**i.d.**) injections: use a 12-16mm, 25-28G needle.
 - When making subcutaneous injections, insert the needle at approximately a 45 degree angle ($\sphericalangle_{45^\circ}$);
 - When making intradermal injections, insert the needle at approximately a 30 degree angle ($\sphericalangle_{30^\circ}$).

● SECONDARY POINTS

1

Anatomical landmarks:

- From the top:

- A) 3-4 cm lateral to the space between the spinous processes of T3 and T4
- B) 3-4 cm lateral to the space between the spinous processes of T7 and T8
- C) 3-4 cm lateral to the space between the spinous processes of T10 and T11

D) 3-4 cm lateral to the space between the spinous processes of T11 and T12

E) 3-4 cm lateral to the space between the spinous processes of T12 and L1.

MDs:

MD-Muscle + MD-Neural.

How to inject: s.c.

● MAIN POINTS

1

Anatomical landmarks::

- From the top:

- A) below the spinous process of T2
- B) below the spinous process of T3
- C) below the spinous process of T6
- D) below the spinous process of T7

E) below the spinous process of T8

F) below the spinous process of T10

G) below the spinous process of T11

H) below the spinous process of T12.

How to inject: i.d.

THORACIC REGION – MD-THORACIC

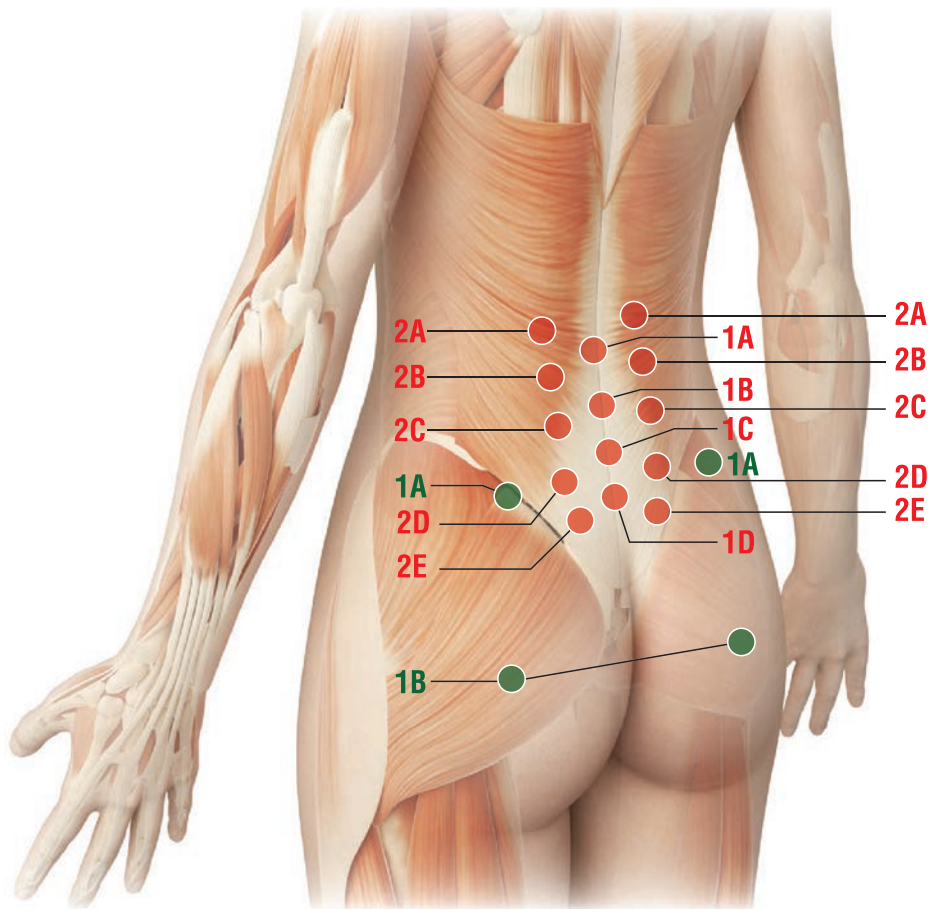
POSSIBLE COMBINATIONS WITH OTHER GUNA COLLAGEN MDs

- Injection in the **main points**

- Thoracic pain due to cartilage degenerative thoracic spine disorders (thoracic osteoarthritis and arthritis):
MD-Thoracic + MD-Poly
- Thoracic pain due to scoliosis:
MD-Thoracic + MD-Muscle + MD-Neural
- Thoracic pain due to thoracic long muscle trigger points:
MD-Thoracic + MD-Muscle
- Pain due to thoracic spine osteophytosis:
MD-Thoracic + MD-Neural + MD-Matrix
- Thoracic pain due to spinal osteoporosis:
MD-Thoracic + MD-Neural + MD-Muscle + MD-Tissue
- Mechanical imbalance (costo-vertebral facet joint syndrome):
MD-Thoracic + MD-Neural + MD-Matrix
- Thoracic spinal ligament syndrome:
MD-Thoracic + MD-Neural
- Thoracic spinal nerve root pain:
MD-Thoracic + MD-Neural.

LUMBAR REGION




MD-LUMBAR



Remarks:

Subcutaneous (**s.c.**) and intradermal injections: use a 12-16mm, 25-28G needle.

Intramuscular (**i.m.**) injections: use a 40mm, 21G needle

- When making subcutaneous injections, insert the needle at approximately a 45° angle ();
- When making intradermal injections, insert the needle at approximately a 30° angle ();
- When making intramuscular injections, insert the needle at a 90° angle ().

● SECONDARY POINTS

1

Anatomical landmarks:

A) On the iliac crest, approximately 8-10 cm from the posterior midline.

MDs:

MD-Muscle + MD-Tissue

How to inject: s.c. or i.d.

B) In the middle of the gluteus maximus muscle, at the same line of the anatomical landmark **A1** (see above).

MDs:

MD-Ischial

How to inject: i.m., at a depth of 2.5-3 cm.

● MAIN POINTS

1

Anatomical landmarks:

- From the top:

A) below the spinous process of L2

B) below the spinous process of L3

C) below the spinous process of L4

D) below the spinous process of L5.

How to inject: i.d. or s.c.

B) 5-6 cm lateral to the space between the spinous processes of L2 and L3

C) 5-6 cm lateral to the space between the spinous processes of L3 and L4

D) 5-6 lateral to the space between the spinous processes of L4 and L5

E) 3-4 cm lateral to the space between the spinous processes of L5 and S1.

How to inject: i.m. at a depth of 10-12 mm.

2

Anatomical landmarks:

- From the top:

A) 5-6 cm lateral to the space between the spinous processes of L1 and L2

LUMBAR REGION – MD-LUMBAR

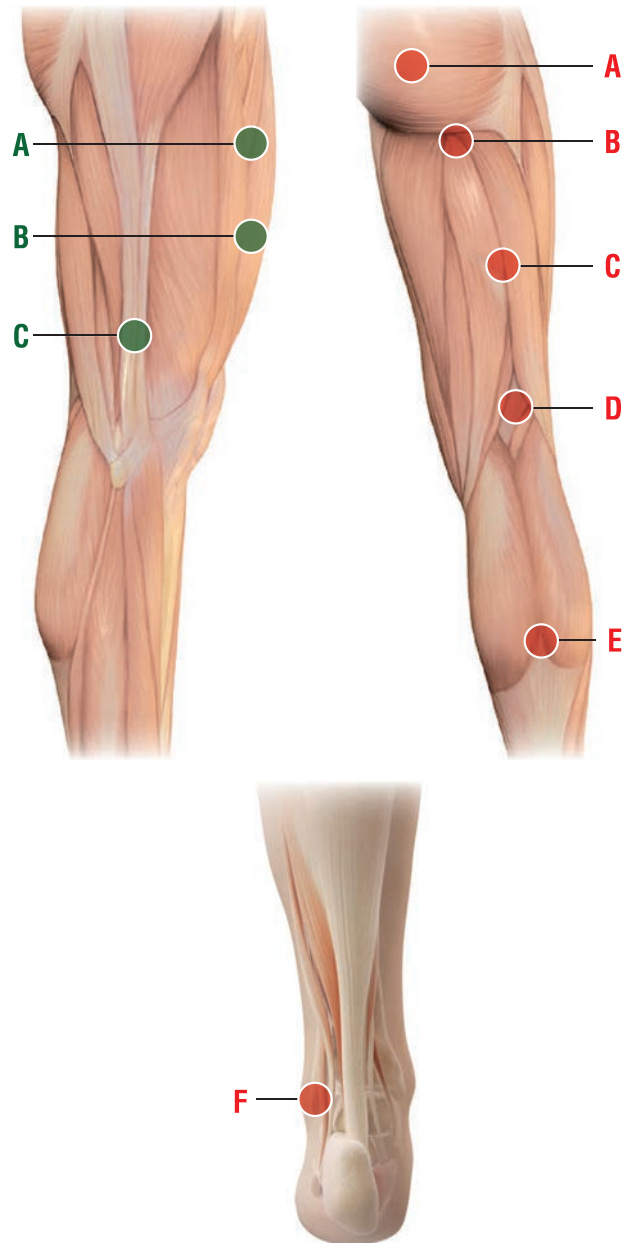
POSSIBLE COMBINATIONS WITH OTHER GUNA COLLAGEN MDs

- Injection in the **main points**

- Lumbar pain secondary to cartilage degenerative lumbar spine disorders (lumbar and lumbar-sacral arthrosis):
MD-Lumbar + MD-Muscle + MD-Neural
- Lumbar vertebral osteophytosis:
MD-Lumbar + MD-Neural + MD-Matrix
- Low-back pain secondary to musculo-tendinous trigger points:
MD-Lumbar + MD-Muscle
- Postural low-back aches:
MD-Lumbar + MD-Neural + MD-Muscle + MD-Tissue
- Lumbar and lumbar-sacral mechanical imbalance:
MD-Lumbar + MD-Neural
- Lumbar and lumbar-sacral spinal ligament syndrome:
MD-Lumbar + MD-Matrix
- Sacro-iliac syndrome:
MD-Lumbar + MD-Neural + MD-Matrix
- Spinal lumbar and lumbar-sacral nerve root pain:
MD-Lumbar + MD-Neural + MD-Ischial.

ISCHIAL NERVE




MD-ISCHIAL



Remarks:

Subcutaneous (**s.c.**) and intradermal injections: use a 12-16mm, 25-28G needle.

Intramuscular (**i.m.**) injections: use a 40mm, 21G needle

- When making subcutaneous injections, insert the needle at approximately a 45 degree angle ();
- When making intradermal injections, insert the needle at approximately a 30 degree angle ();
- When making intramuscular injections, insert the needle at approximately a 90 degree angle ().

● SECONDARY POINTS

Anatomical landmarks:

- A) Midway of the anterior thigh, about 20 cm above the upper edge of the patella
- B) Midway of the anterior thigh, about 15 cm above the upper edge of the patella.

MDs:

MD-Neural + MD-Matrix.

How to inject: i.m. or s.c.

- C) Patient standing straight, on the lateral surface of the thigh, at the point where the patient's middle finger touches the thigh.

MDs:

MD-Neural + MD-Matrix.

How to inject: s.c.

● MAIN POINTS

Anatomical landmarks:

- A) Midway of the gluteus maximus muscle, 5-6 cm lateral from the posterior midline
- B) Midway of the gluteal-femoral fold
- C) Midway of the posterior surface of the thigh, midway between the anatomical landmark B (see above) and the anatomical landmark D (see below)
- D) Midway of the popliteal crease
- E) Point of intersection between the two

muscles of the gastrocnemius and the tendon of the soleus muscle

- F) 3-4 cm from the tip of the lower and posterior external malleolus.

How to inject:

A, B and C : i.m.

D : i.d.

E, F : s.c.

ISCHIAL NERVE – MD-ISCHIAL

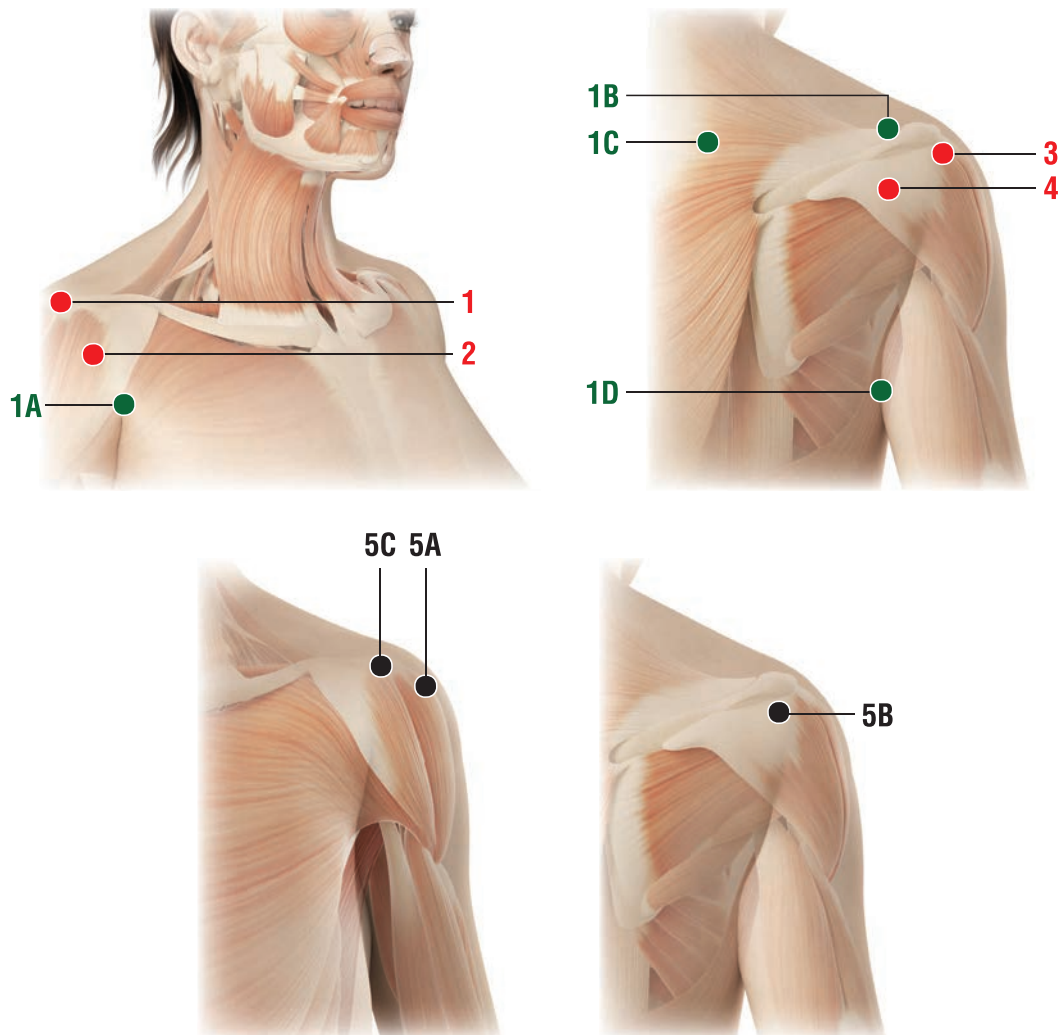
POSSIBLE COMBINATIONS WITH OTHER GUNA COLLAGEN MDs

- Injection in the **main points**

- Sciatic pain:
MD-Ischial
- Lumbar-sciatic pain:
MD-Ischial + MD-Lumbar + MD-Neural
- Nerve pain in the lower lumbar spine:
MD-Ischial + MD-Muscle
- Persistent sciatic pain due to post-surgery treatment of disc herniation L4-L5, L5-S1:
MD-Ischial + MD-Neural
- Morton's neuroma:
MD-Ischial + MD-Neural + MD-Tissue.

SHOULDER

MD-SHOULDER






Remarks:

Subcutaneous (**s.c.**) and intradermal injections: use a 12-16mm, 25-28G needle.

Intramuscular (**i.m.**) injections: use a 40mm, 21G needle

Intra-articular injections (**i.a.**): use a dedicated needle.

- When making subcutaneous injections, insert the needle at approximately a 45 degree angle ();
- When making intradermal injections, insert the needle at approximately a 30 degree angle ();
- When making intramuscular injections, insert the needle at approximately a 90 degree angle ().

● SECONDARY POINTS

1

Anatomical landmarks:

- A) The highest point of the anterior axillary fold
- B) Point of intersection between the supraspinatus muscle and the posterior aspect of the acromion
- C) 7 cm lateral to the spinous process of C7

D) Highest point of the posterior axillary fold.

MDs:

MD-Muscle + MD-Neural.

How to inject: i.m. at a depth of 0.8 - 1 cm.

● MAIN POINTS

1

Anatomical landmarks:

Lateral-external surface of the shoulder, in the acromioclavicular joint, the dimple that is formed by lifting the arm.

How to inject: s.c., i.d., i.a.

2

Anatomical landmark:

Midway of the segment joining the acromioclavicular joint to the highest point of the anterior axillary fold (Secondary point 1A).

How to inject: Peri-articular injection at a 90 degree angle to the skin surface, very close to the joint capsule.
- Alternatively: s.c.

3

Anatomical landmark:

Upper limb in horizontal position; postero-external surface, in the dimple that is formed between the acromion and the greater tubercle of the humerus.

How to inject: Peri-articular injection at a 90 degree angle to the skin surface, very close to the joint capsule.
- Alternatively: s.c.

4

Anatomical landmark:

On the vertical line drawn through the posterior axillary fold (Secondary point 1D), in the dimple of the posterior aspect of the shoulder joint.

How to inject: i.m., s.c.

5

Anatomical landmarks:

- 1) The shoulder joint (glenohumeral joint) can be injected in the anterior, lateral and upper aspect. It is generally easier to access in these locations.
 - The lateral approach **5A** and posterior approach **5B** are the most used in ambulatory care
- 2) The acromioclavicular joint is easy to access.
 - The approach can be posterosuperior (**5C**).

How to inject: Intra-articular.

A common standard needle for i.m. injection can be easily used.

SHOULDER – MD-SHOULDER

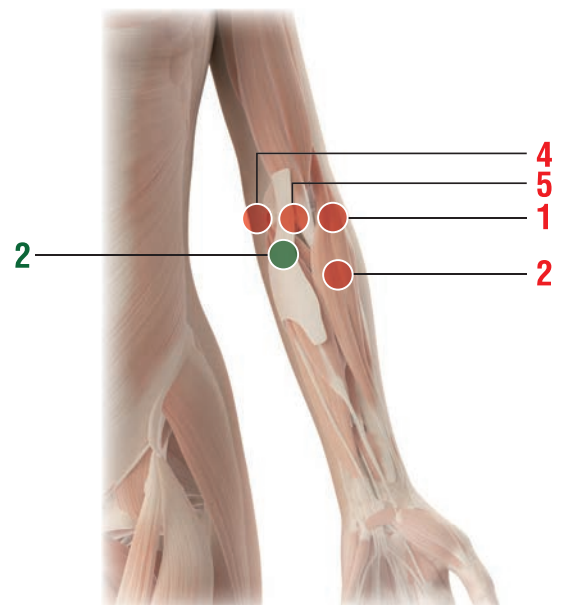
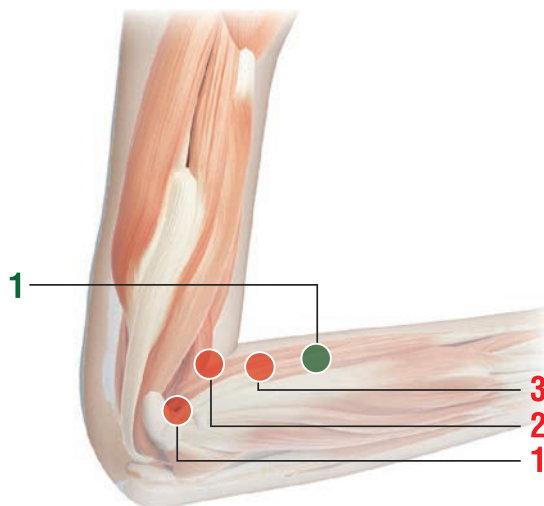
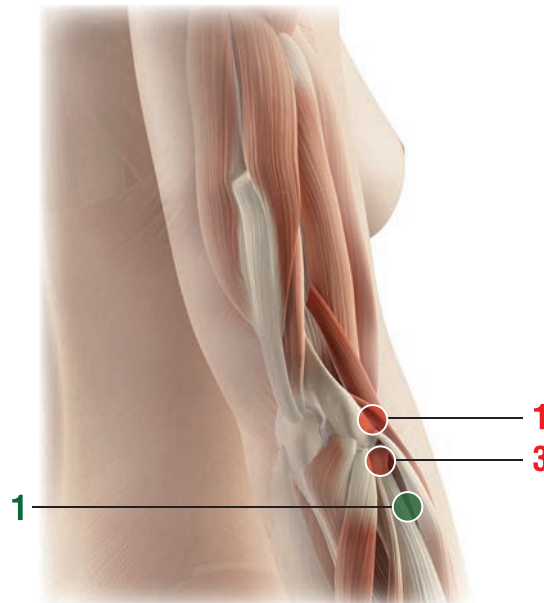
POSSIBLE COMBINATIONS WITH OTHER GUNA COLLAGEN MDs

- Injection in the **main points**

- Shoulder-arm polyarthritis:
MD-Shoulder + MD-Poly
- Rotator cuff syndrome:
MD-Shoulder + MD-Muscle + MD-Tissue
- Shoulder-arm syndrome:
MD-Shoulder + MD-Neural + MD-Muscle
- Frozen shoulder:
MD-Shoulder + MD-Muscle
- Shoulder pain due to dislocation (pre and post relocation):
MD-Shoulder + MD-Neural.

ELBOW

MD-SHOULDER



Remarks:

Subcutaneous (**s.c.**) and intradermal injections: use a 12-16mm, 25-28G needle.

Intramuscular (**i.m.**) injections: use a 40mm, 21G needle

- When making subcutaneous injections, insert the needle at approximately a 45 degree angle ($\angle 45^\circ$);
- When making intradermal injections, insert the needle at approximately a 30 degree angle ($\angle 30^\circ$);
- When making intramuscular injections, insert the needle at approximately a 90 degree angle ($\angle 90^\circ$).

● SECONDARY POINT

EPICONDYLITIS

1

Anatomical landmark:

2-3 cm more distal from the anatomical landmark 2 of the main Points.

MDs:

MD-Muscle.

How to inject: s.c. or i.m. (at a depth of 5-6 mm).

EPITROCHLEITIS

2

Anatomical landmark:

The midway point of the elbow crease, on the internal side of the biceps tendon.

MDs:

MD-Matrix + MD-Tissue.

How to inject: s.c. or i.d.

● MAIN POINTS

EPICONDYLITIS

1

Anatomical landmark:

Elbow flexed at a 90 degree angle, just in front of the epicondyle.

MDs:

MD-Shoulder + MD-Poly.

How to inject: s.c. at a 90 degree angle to the bone surface.

2

Anatomical landmark:

At the external tip of the folded elbow flexed at a 90 angle.

MDs:

MD-Muscle.

How to inject: s.c. or i.m. (at a depth of 5-6 mm).

3

Anatomical landmark:

Elbow flexed at a 90 degree angle approximately 4 cm in front of the anatomical landmark 2.

MDs:

MD-Muscle.

How to inject: s.c. or i.m. (at a depth of 5-6 mm).

EPITROCHLEITIS

4

Anatomical landmark:

On the posteroanterior aspect of the elbow, between the medial condyle of the humerus (trochlea) and the olecranon.

MDs:

MD-Shoulder + MD-Poly.

How to inject: s.c. at a 90 degree angle to the bone surface.

5

Anatomical landmark:

At the tip of the internal crease of the elbow flexed at a 90 degree angle.

MDs:

MD-Muscle.

How to inject: s.c. or i.m. (at a depth of 4-5 mm).

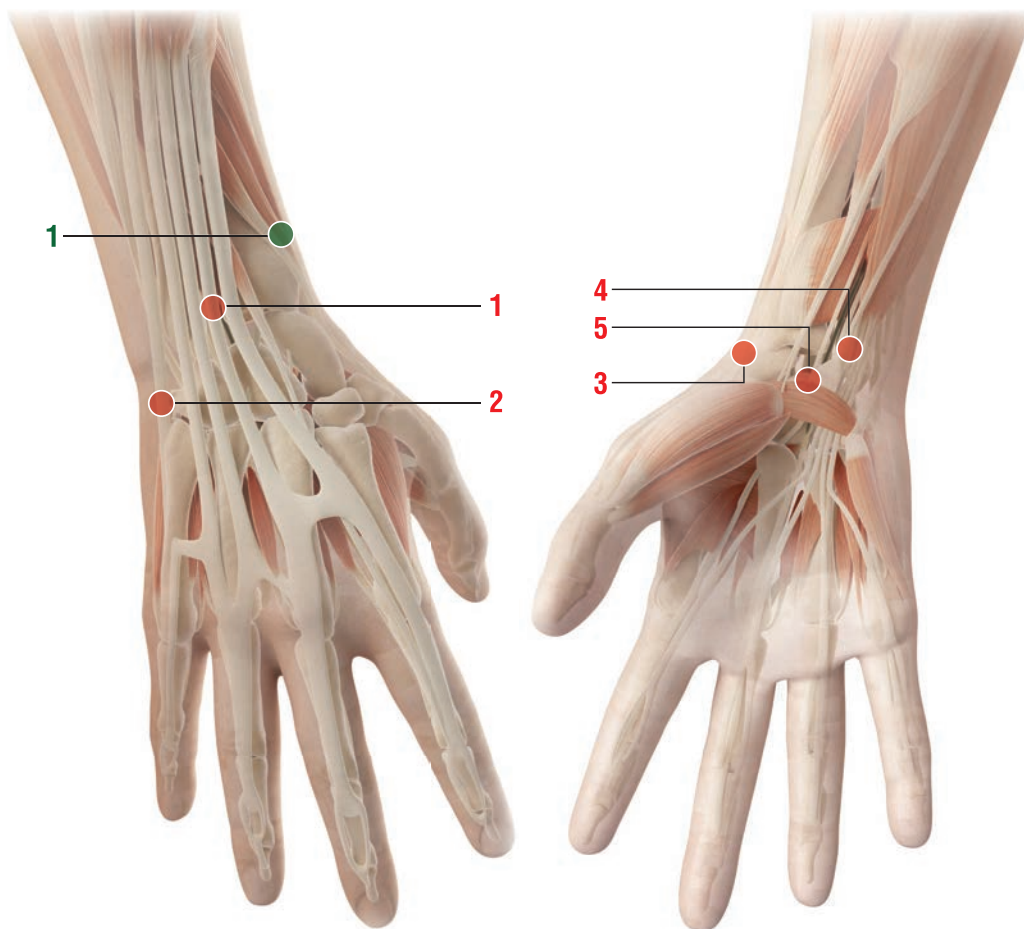
ELBOW – MD-SHOULDER

POSSIBLE COMBINATIONS WITH OTHER GUNA COLLAGEN MDs - Injection in the **main points**

- Epicondylitis
 - Epitrochleitis
- As for the MDs to be injected, please see main and secondary points
- De Quervain syndrome (stenosing tenosynovitis): **MD-Shoulder + MD-Neural**

WRIST

MD-POLY MD-SMALL JOINTS



Remarks:

Subcutaneous (**s.c.**) and intradermal injections: use a 12-16mm, 25-28G needle.

- When making subcutaneous injections, insert the needle at approximately a 45 degree angle ($\sphericalangle_{45^\circ}$);
- When making intradermal injections, insert the needle at approximately a 30 degree angle ($\sphericalangle_{30^\circ}$);

● SECONDARY POINT

1

On the external edge of the radius (proximal to the dorsal surface of the forearm), approximately 6-7 cm from the flexion crease of the wrist.

MDs:

MD-Poly + MD-Neural.

How to inject: s.c.

● MAIN POINTS

1

Anatomical landmark:

On the dorsal surface of the forearm, approximately 2 cm above the dorsal crease of the wrist, on the internal side of the radius (hand in a supinated position).

How to inject: s.c.

2

Anatomical landmark:

On the internal border of the hand, in a dimple between the 5th metacarpal and the hamate bone.

How to inject: s.c.

3

Anatomical landmark:

In the radial depression, on the flexion crease of the wrist.

On the external border of the hand in a dimple, above the head of the 1st metacarpal bone.

How to inject: s.c.

4

Anatomical landmark:

2 cm above the flexion crease of the wrist, between the pisiform bone and styloid process of the ulna.

How to inject: s.c.

5

Anatomical landmark:

Midway of the flexion crease of the wrist.

How to inject: s.c.

WRIST – MD-POLY, MD-SMALL JOINTS

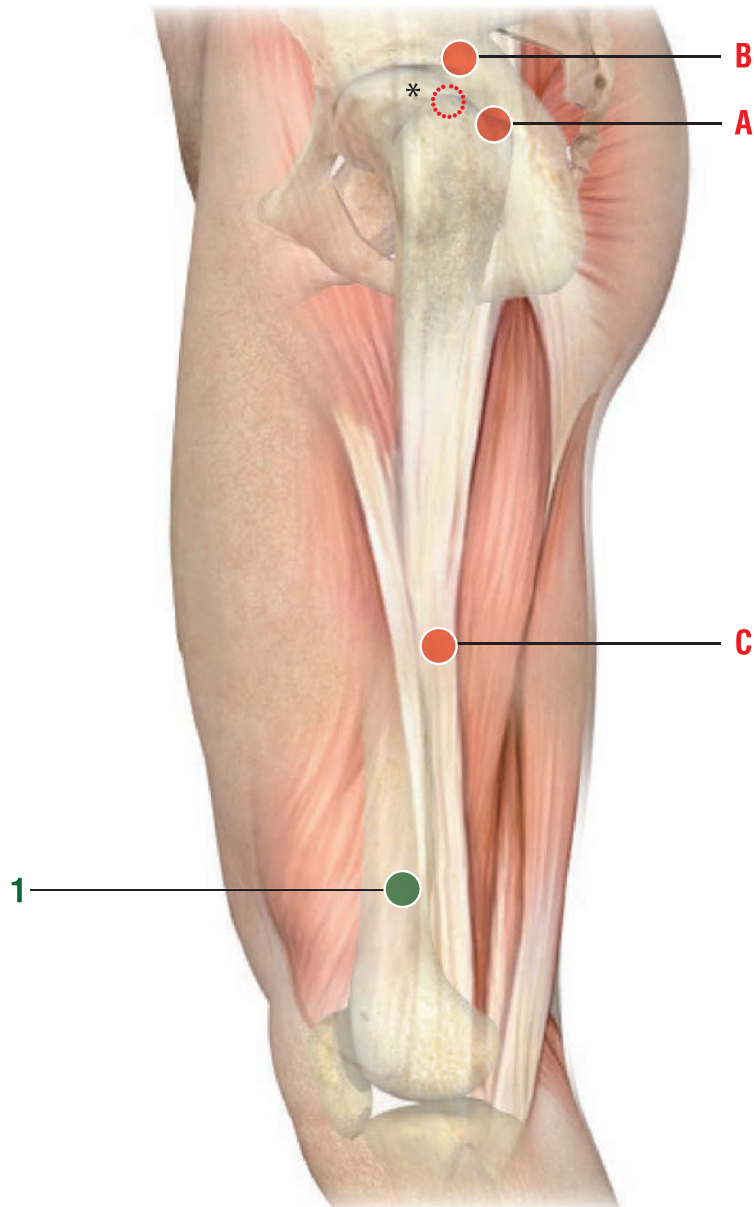
POSSIBLE COMBINATIONS WITH OTHER GUNA COLLAGEN MDs

- Injection in the **main points**

- Arthritis of the fingers (local painful points):
MD-Small Joints
- Rhizarthrosis of the thumb (Forestier disease):
MD-Small Joints + MD-Poly + MD-Neural
- Carpal-tunnel syndrome:
MD-Small Joints + MD-Neural
- De Quervain disease (see also Elbow core directions on use and combinations with other MDs):
MD-Small Joints + MD-Neural
- Rheumatoid arthritis of the hand:
MD-Small Joints + MD-Poly
- Hand tendon pain due to prolonged immobilization:
MD-Small Joints + MD-Matrix + MD-Tissue.

HIP

MD-HIP





Note:

Subcutaneous (**s.c.**) and intradermal injections: use a 12-16mm, 25-28G needle.

Intramuscular (**i.m.**) injections: use a 40mm, 21G needle

Intra-articular injections: use a dedicated needle.

- When making subcutaneous injections, insert the needle at approximately a 45 degree angle ().
- When making intramuscular injections, insert the needle at approximately a 90 degree angle ().

● SECONDARY POINT

1

Anatomical landmark:

8 cm above the external femoral condyle.

MDs:

MD-Muscle.

How to inject: i.m. at a depth of 1 cm, insert the needle at a 90 degree angle to the skin surface

- Alternatively: s.c.

● MAIN POINTS

Anatomical landmark:

A) Patient in orthostatic position with feet together, posterior margin of the greater trochanter. With patient lying on the healthy side, the anatomical landmark is localized on the apex of the greater trochanter*.

B) 2 cm above and in front of the highest margin of the greater trochanter (anatomical landmark **A**).

C) Patient in orthostatic position: upper limb along the trunk, point on the thigh touched by the top joint of the middle finger.

How to inject:

For **A)** and **B)**: i.a., p.a.

- Alternatively:

For **A)** and **B)**: i.m. at a depth of 2 cm; needle inclination towards the hip joint

For **C)**: i.m. at a depth of 1 cm; insert the needle at a 90° degree angle from to the skin surface.

HIP – MD-HIP

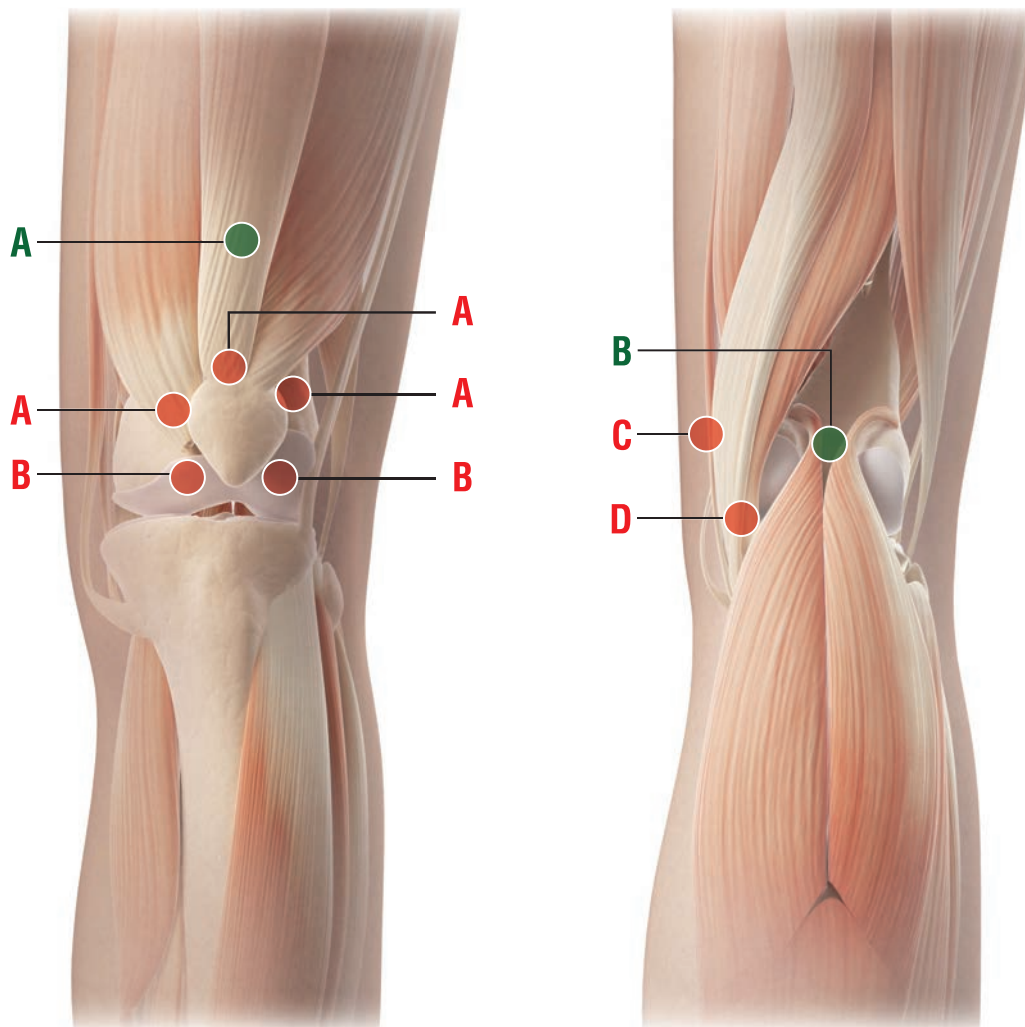
POSSIBLE COMBINATIONS WITH OTHER GUNA COLLAGEN MDs

- Injection in the **main points**

- Hip joint osteoarthritis:
MD-Hip
- Hip joint capsule inflammation:
MD-Hip + MD-Matrix
- Hip joint osteoarthritis with rheumatoid arthritis:
MD-Hip + MD-Poly
- Hip joint pain of muscle origin:
MD-Hip + MD-Muscle + MD-Neural
- Hip joint pain of nerve origin (burning hip):
MD-Hip + MD-Neural
- Hip joint pain due to prolonged bed rest:
MD-Hip + MD-Matrix + MD-Tissue.

KNEE



MD-KNEE



Remarks:

Subcutaneous (**s.c.**) and intradermal injections: use a 12-16mm, 25-28G needle.

Intramuscular (**i.m.**) injections: use a 40mm, 21G needle

- While making subcutaneous injections, insert the needle at approximately a 45 degree angle ();
- While making intramuscular injections, insert the needle at approximately a 90 degree angle (.

The three most common sites of **i.a.** injections of the knee are: anterolateral, anteromedial (patient positioned with the knee flexed at 90 degrees) and lateral midway of the patella (extended knee).

Intra-articular (**i.a.**) injections: use a 50mm, 21G needle.

● SECONDARY POINTS

Anatomical landmarks:

- A) 4-5 cm above the maximum convexity of the patella
- B) midpoint of the popliteal fossa.

MDs:

- For A): **MD-Muscle**.
- B): **MD-Matrix**.

How to inject:

For A) and B): s.c.

● MAIN POINTS

1

Anterior anatomical landmarks:

- A) Top margin of the patella and 2 cm (right and left) from this area follow the curved edge of the patella.
- B) inferior-lateral margin of the patella, at the height of the interspace of the knee joint.

How to inject: s.c. or i.a.
only for lateral A.

2

Posterior anatomical landmarks:

- C) On the inner surface of the knee, at the height of the interspace of the knee joint
- D) On the inner surface of the knee, on the upper edge of the upper end of the tibia, proximal to the joint interspace.

How to inject: s.c., 5-6 mm deep, at a 90 degree angle to the skin surface.

KNEE – MD-KNEE

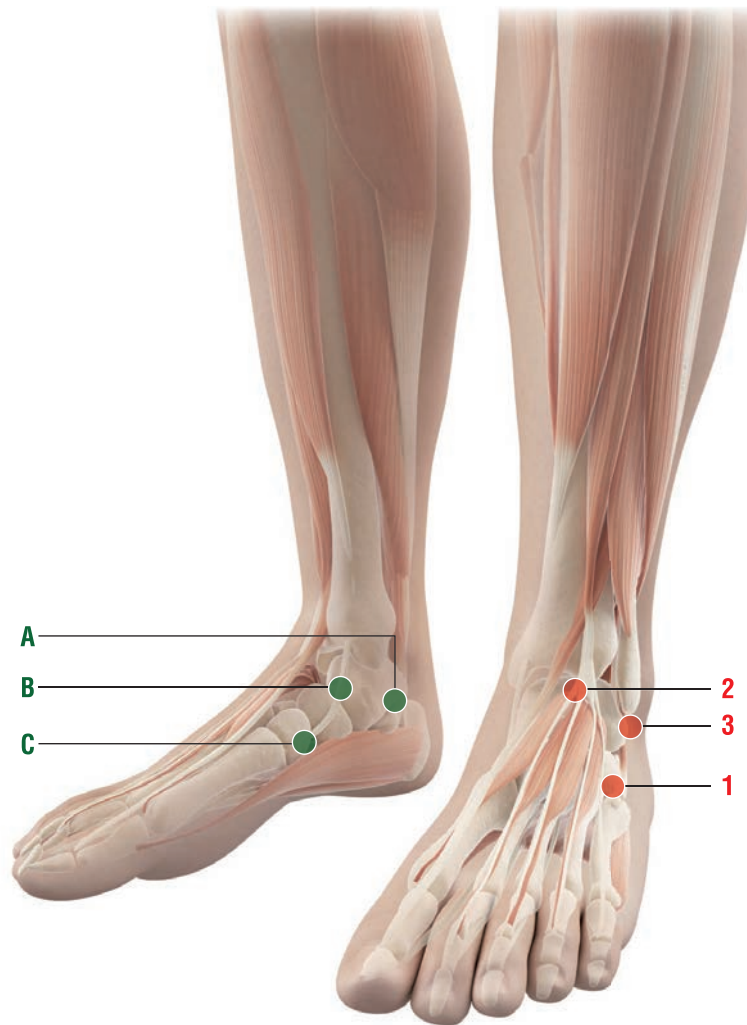
POSSIBLE COMBINATIONS WITH OTHER GUNA COLLAGEN MDs

- Injection in the **main points**

- Knee arthrosis:
MD-Knee + MD-Poly
- Painful knee due to rheumatoid arthritis or other autoimmune diseases:
MD-Knee + MD-Poly
- Knee acute and chronic arthrosynovitis secondary to injury, osteoarthritis or rheumatoid arthritis:
MD-Knee + MD-Poly
- Arthrosynovitis, acute and chronic post-traumatic or post-surgery arthrosynovitis:
MD-Knee + MD-Matrix
- Traumatic lesions of cruciate or collateral ligaments of the knee:
MD-Knee + MD-Tissue
- Meniscal lesions:
MD-Knee + MD-Poly
- Knee joint preparation to meniscectomy:
MD-Knee + MD-Muscle
- Maintenance therapy after knee surgery:
MD-Knee + MD-Muscle + MD-Neural.



ANKLE

MD-SMALL JOINTS MD-POLY



Remarks:

Subcutaneous (**s.c.**) injections: 12-16 mm , 25-28 G needle.

- When making subcutaneous injections, insert the needle at approximately a 45 degree angle ();
- When making intramuscular injections, insert the needle at approximately a 90 degree angle ().

● SECONDARY POINTS

1

Anatomical landmarks:

- A) 2 cm below and posterior to the medial malleolus, on the upper edge of the heel
- B) On the inner edge of the instep, 2 cm anterior and inferior to the medial malleolus
- C) On the border between the scaphoid and the 1st cuneiform bone.

MDs:

MD-Small Joints + MD-Tissue.

How to inject: 5 mm, at a 90 degree angle to the skin surface.

Only for **B**: i.a.

● MAIN POINTS

1

Anatomical landmark:

2 cm anterior and inferior to the external malleolus on the calcaneal-cuboid joint.

How to inject: 5 mm, at a 90 degree angle to the skin surface.

2

Anatomical landmark:

On the central fold of extension of the foot (instep), immediately below the tibia.

How to inject: 5 mm, at a 90 degree angle to the skin surface.

3

Anatomical landmark:

1 cm below and slightly behind the external malleolus, just above the heel.

How to inject: 5 mm, at a 90 degree angle to the skin surface.

ANKLE – MD-SMALL JOINTS, MD-POLY

POSSIBLE COMBINATIONS WITH OTHER GUNA COLLAGEN MDs


- Injection in the **main points**

- Arthrosis pain due to hammer toe:
MD-Small Joints + MD-Poly
- Metatarsal pain:
MD-Small Joints
- Metatarsal pain accompanied by Morton's neuroma:
MD-Small Joints + MD-Poly + MD-Neural
- Rheumatoid arthritis of the foot:
MD-Small Joints + MD-Poly + MD-Matrix
- Foot tendon pain due to prolonged immobilization:
MD-Small Joints + MD-Poly + MD-Matrix.

REFERENCES

1. Milani L. A new and refined injectable treatment for musculoskeletal disorder. Bioscaffold properties of collagen and its clinical use. *Physiological Regulating Medicine* 2010/1; 3-15.
2. Fung DT, Sereysky JB, Basta-Pljakic J, Laudier DM, Huq R, Jepsen KJ, Schaffler MB, Flatow EL. Second harmonic generation imaging and Fourier transform spectral analysis reveal damage in fatigue-loaded tendons. *Ann Biomed Eng.* 2010 May;38(5):1741-51.
3. Christensen B, Dandanell S, Kjaer M, Langberg H. Effect of anti-inflammatory medication on the running-induced rise in patella tendon collagen synthesis in humans. *J Appl Physiol* (1985). 2011 Jan;110(1):137-41.
4. Linsenmayer, T.F. (1991) Collagen. In: "Cell Biology of the Extracel-Mar Matrix," Hay, E.D. (ed). New York: Plenum Press, pp. 7-44.
5. Friedrichs J, Taubenberger A, Franz CM, Muller DJ. Cellular remodelling of individual collagen fibrils visualized by time-lapse AFM. *J Mol Biol.* 2007 Sep 21;372(3):594-607.
6. del Nogal M, Luengo A, Olmos G, Lasa M, Rodriguez-Puyol D, Rodriguez-Puyol M, Calleros L. Balance between apoptosis or survival induced by changes in extracellular-matrix composition in human mesangial cells: a key role for ILK-NFκB pathway. *Apoptosis.* 2012 Dec;17(12):1261-74.
7. Tsai KS, Kao SY, Wang CY, Wang YJ, Wang JP, Hung SC. Type I collagen promotes proliferation and osteogenesis of human mesenchymal stem cells via activation of ERK and Akt pathways. *J Biomed Mater Res A.* 2010 Sep 1;94(3):673-82.
8. Hynes RO. Integrins: bidirectional, allosteric signaling machines. *Cell.* 2002 Sep 20;110(6):673-87.
9. Massoud El. Healing of subcutaneous tendons: Influence of the mechanical environment at the suture line on the healing process. *World J Orthop.* 2013 Oct 18;4(4):229-40.
10. Kook SH, Jang YS, Lee JC. Involvement of JNK-AP-1 and ERK-NF-κB signaling in tension-stimulated expression of type I collagen and MMP-1 in human periodontal ligament fibroblasts. *J Appl Physiol* (1985). 2011 Dec;111(6):1575-83.
11. Silbernagel KG, Brorsson A, Lundberg M. The majority of patients with Achilles tendinopathy recover fully when treated with exercise alone: a 5-year follow-up. *Am J Sports Med.* 2011 Mar;39(3):607-13.
12. Brandão RA, Costa BS, Dellaretti MA, de Carvalho GT, Faria MP, de Sousa AA. Efficacy and safety of a porcine collagen sponge for cranial neurosurgery: a prospective case-control study. *World Neurosurg.* 2013 Mar-Apr;79(3-4):544-50.
13. Sage RJ, Lopiccolo MC, Liu A, Mahmoud BH, Tierney EP, Kouba DJ. Subcuticular incision versus naturally sourced porcine collagen filler for acne scars: a randomized split-face comparison. *Dermatol Surg.* 2011 Apr;37(4):426-31.
14. Catena F, Ansaloni L, Gazzotti F, Gagliardi S, Di Saverio S, D'Alessandro L, Pinna AD. Use of porcine dermal collagen graft (Permacol) for hernia repair in contaminated fields. *Hernia.* 2007 Feb;11(1):57-60.
15. Narins RS, Brandt FS, Lorenc ZP, Maas CS, Monheit GD, Smith SR, McIntyre S. A randomized, multicenter study of the safety and efficacy of Dermicol-P35 and non-animal-stabilized hyaluronic acid gel for the correction of nasolabial folds. *Dermatol Surg.* 2007 Dec;33 Suppl 2:S213-21; discussion S221.
16. Solish NJ. Assessment of recovery time for the collagen products Dermicol-P35 27G and 30G. *J Am Acad Dermatol.* 2010 May;62(5):824-30.
17. Henstock JR, Canham LT, Anderson SI. Silicon: the evolution of its use in biomaterials. *Acta Biomater.* 2015;11:17-26.
18. Muhammad N, Saeed M, Khan H. Antipyretic, analgesic and anti-inflammatory activity of *Viola betonicifolia* whole plant. *BMC Complement Altern Med.* 2012 May 2;12:59.

19. Erdemoglu N, Akkol EK, Yesilada E, Caliş I. Bioassay-guided isolation of anti-inflammatory and antinociceptive principles from a folk remedy, *Rhododendron ponticum* L. leaves. *J Ethnopharmacol.* 2008 Sep 2;119(1):172-8.
20. Grieve, M., 1994. "A Modern Herbal", Lylel. Tiger Books International, London.
21. Krenn L, Beyer G, Pertz HH, Karall E, Kremser M, Galambosi B, Melzig MF. In vitro antispasmodic and anti-inflammatory effects of *Drosera rotundifolia*. *Arzneimittelforschung.* 2004;54(7):402-5.
22. Nawash O, Shudiefat M, Al-Tabini R, Al-Khalidi K. Ethnobotanical study of medicinal plants commonly used by local Bedouins in the Badia region of Jordan. *J Ethnopharmacol.* 2013 Jul 30;148(3):921-5.
23. Hussain AI, Rathore HA, Sattar MZ, Chatha SA, Sarker SD, Gilani AH. *Citrullus colocynthis* (L.) Schrad (bitter apple fruit): a review of its phytochemistry, pharmacology, traditional uses and nutritional potential. *J Ethnopharmacol.* 2014 Aug 8;155(1):54-66.
24. Gilani AH, Khan AU, Subhan F, Khan M. Antispasmodic and bronchodilator activities of St John's wort are putatively mediated through dual inhibition of calcium influx and phosphodiesterase. *Fundam Clin Pharmacol.* 2005 Dec;19(6):695-705.
25. Tang X, Liu J, Dong W, Li P, Li L, Lin C, Zheng Y, Hou J, Li D. The cardioprotective effects of citric Acid and L-malic Acid on myocardial ischemia/reperfusion injury. *Evid Based Complement Alternat Med.* 2013;2013:820695.
26. Turunc Bayrakdar E, Uyanikgil Y, Kanit L, Koylu E, Yalcin A. Nicotinamide treatment reduces the levels of oxidative stress, apoptosis, and PARP-1 activity in A β (1-42)-induced rat model of Alzheimer's disease. *Free Radic Res.* 2014 Feb;48(2):146-58.
27. Masaki H. Role of antioxidants in the skin: anti-aging effects. *J Dermatol Sci.* 2010 May;58(2):85-90.
28. Wilson JX. Mechanism of action of vitamin C in sepsis: ascorbate modulates redox signaling in endothelium. *Biofactors.* 2009 Jan-Feb;35(1):5-13.
29. Ngamphaiboon N, Sweeney R, Wetzler M, Wang ES. Pyridoxine treatment of vincristine-induced cranial polyneuropathy in an adult patient with acute lymphocytic leukemia: Case report and review of the literature. *Leuk Res.* 2010 Aug;34(8):e194-6.
30. Keil SD, Kiser P, Sullivan JJ, Kong AS, Reddy HL, Avery A, Goodrich RP. Inactivation of *Plasmodium* spp. in plasma and platelet concentrates using riboflavin and ultraviolet light. *Transfusion.* 2013 Oct;53(10):2278-86.
31. Lyss G, Knorre A, Schmidt TJ, Pahl HL, Merfort I. The anti-inflammatory sesquiterpene lactone helenalin inhibits the transcription factor NF-kappaB by directly targeting p65. *J Biol Chem.* 1998 Dec 11;273(50):33508-16.
32. Jurkiewicz A, Ryszka P, Anielska T, Waligórski P, Białońska D, et al. Optimization of culture conditions of *Arnica montana* L.: effects of mycorrhizal fungi and competing plants. *Mycorrhiza.* 2010 Jun;20(5):293-306.
33. Schütz C, Quitschau M, Hamburger M, Potterat O. Profiling of isoflavonoids in *Iris germanica* rhizome extracts by microprobe NMR and HPLC-PDA-MS analysis. *Fitoterapia.* 2011 Oct;82(7):1021-6.
34. Rahman AU, Nasim S, Baig I, Jalil S, Orhan I, et al. Anti-inflammatory isoflavonoids from the rhizomes of *Iris germanica*. *J Ethnopharmacol.* 2003 Jun;86(2-3):177-80.
35. Trautvetter U, Neef N, Leiterer M, Kiehnkopf M, Kratzsch J, et al. Effect of calcium phosphate and vitamin D₃ supplementation on bone remodelling and metabolism of calcium, phosphorus, magnesium and iron. *Nutr J.* 2014 Jan 17;13:6.



Medical device

CE 0373

<http://collagenmd.guna.com>



GUNA S.p.a.

Via Palmanova, 71 - 20132 Milan - Italy

T. +39 02 280181 - export@guna.it

Company with Quality Management System

UNI CEI EN ISO 13485:2016

certified by Certiquality